# Puberty - Early Normal and Abnormal Development

Paul Hofman 2009

# Case Scenario 1

6 year old girl with 1 year hx of breast development. Otherwise well with no past hx of note.

O/E she has

- Tanner 2-3 breast development
- Tanner 1 pubic hair
- Height on 90th%ile

Does this patient have precocious puberty?

# Definitions

Precocious puberty - < 8.5 years girls
< 9.5 years boys

A symptom NOT a diagnosis

Major medical complication is short stature

# Definitions

First signs of puberty

girls - breast development/ growth spurt

boys - testicular growth (> 4ml)
(growth spurt late)

# Definitions

Oestrogen action = Breast Development

Androgen action = Pubic hair, acne, body odour, axillary hair, hirsutism, genital enlargement

# Definition

Normal Puberty -

- Central activation of the H-P-Gonadal axis
- ***Progressive sequential*** changes
- Appropriate rate (over 3-4 years)

**Sustained, ongoing sex steroid action**

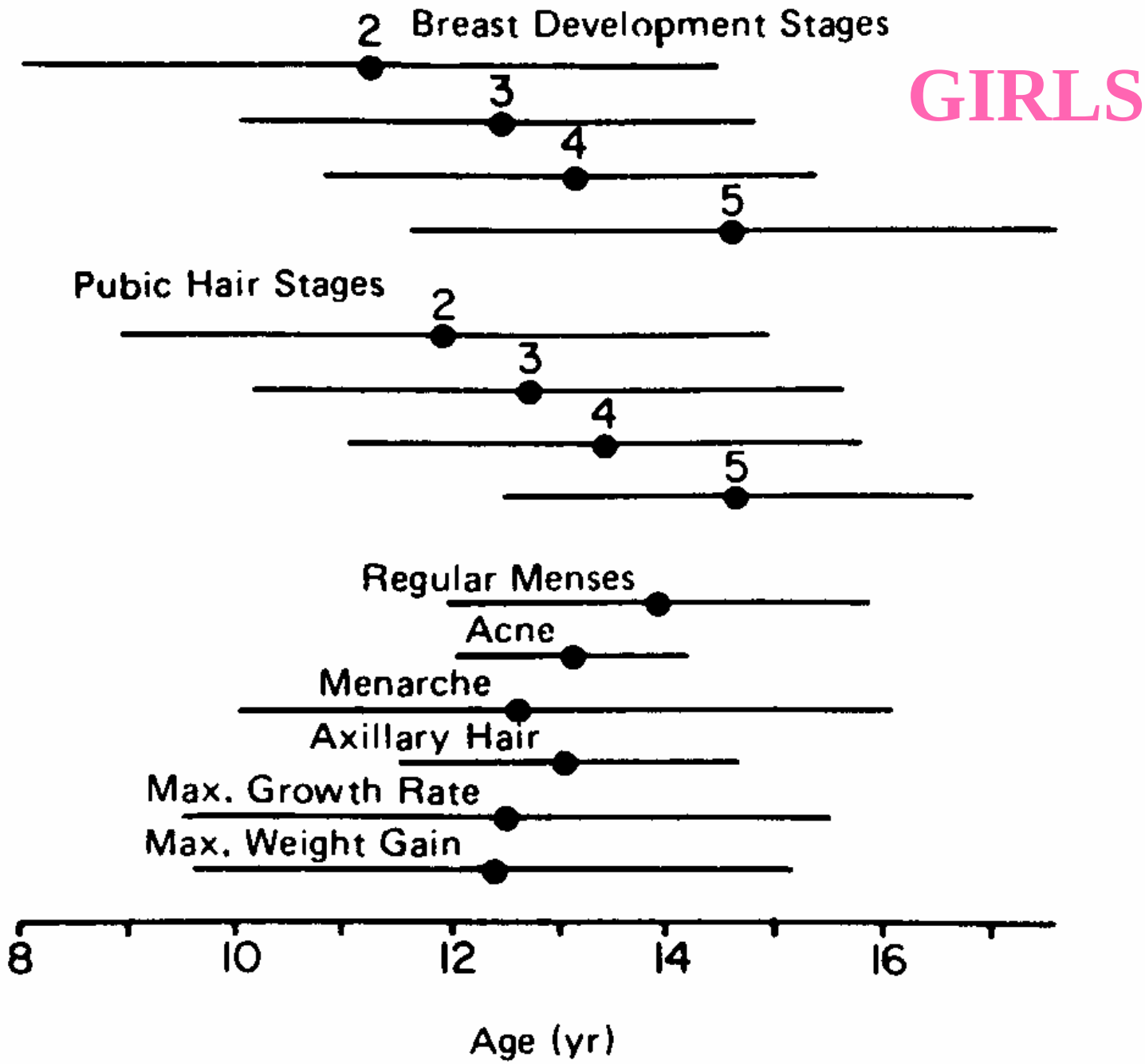
GIRLS
Breast Development Stages
2
3
4
5
Pubic Hair Stages
2
3
4
5
Regular Menses
Acne
Menarche
Axillary Hair
Max. Growth Rate
Max. Weight Gain
8
10
12
14
16
Age (yr)

# BOYS

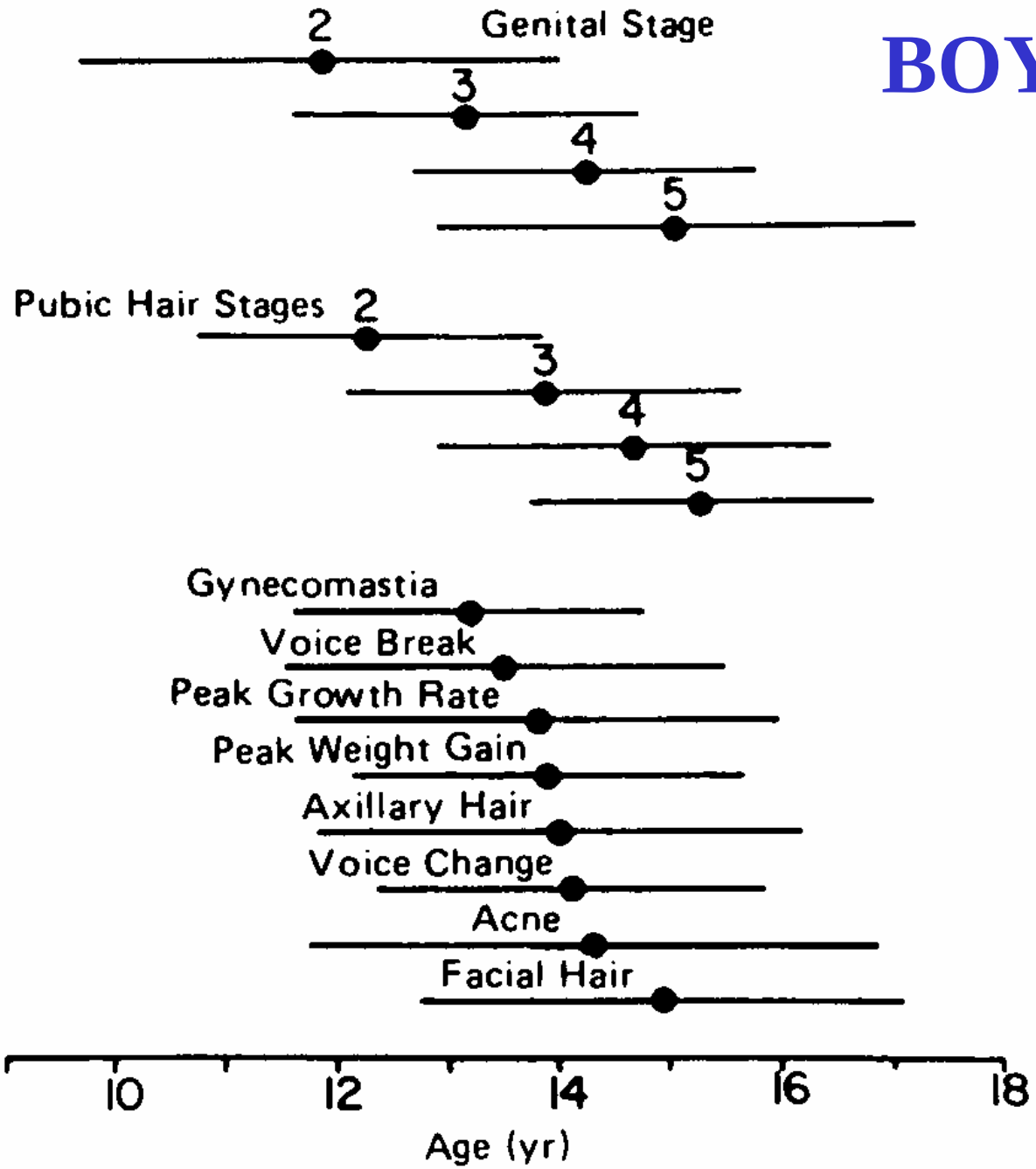
Genital Stage
2
3
4
5
Pubic Hair Stages
2
3
4
5
Gynecomastia
Voice Break
Peak Growth Rate
Peak Weight Gain
Axillary Hair
Voice Change
Acne
Facial Hair
10
12
14
16
18
Age (yr)

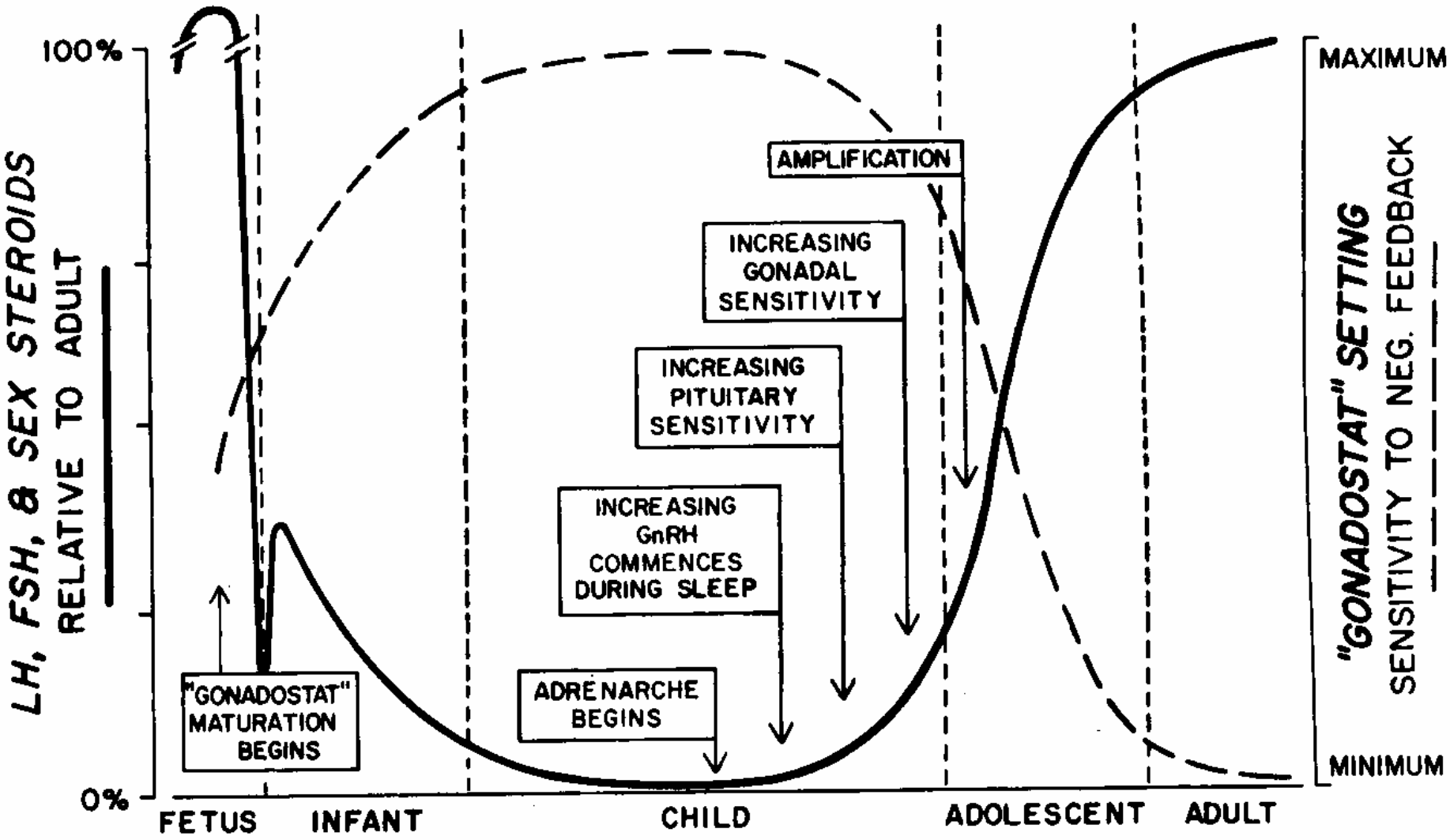
100%
0%
LH, FSH, & SEX STEROIDS
RELATIVE TO ADULT
"GONADOSTAT" MATURATION BEGINS
ADRENARCHE BEGINS
INCREASING GnRH COMMENCES DURING SLEEP
INCREASING PITUITARY SENSITIVITY
INCREASING GONADAL SENSITIVITY
AMPLIFICATION
FETUS
INFANT
CHILD
ADOLESCENT
ADULT
MAXIMUM
MINIMUM
"GONADOSTAT" SETTING
SENSITIVITY TO NEG. FEEDBACK

# Signs of sustained sex steroid effect

| | |
|---|---|
| Growth | height velocity<br>height compared to mid parental height |
| Breasts | progressive development |
| Introitus | pink-red epithelium pre oestrogen<br>white-pink with sustained oestrogen exposure<br>(cornification of epithelium) |

# Investigations for sustained sex steroid effect

**Bone Age** (X-ray L hand and wrist)

**USS pelvis** Uterine size/ volume, sometimes useful info on ovaries.

***Unhelpful/ Useless/ Uninterpretable tests***

FSH and LH
Testosterone
Oestradiol (the assay is less sensitive than the bioassay of growth and breast development

# Case Scenario 1

| | |
|---|---|
| Midparental Height | 25th%ile |
| Introitus | white-pink colour |
| Bone Age | 10 years (CA 6 years) |

Interpretation - Highly suggestive of sustained oestrogen exposure/ action.

Warrants urgent paediatric endocrine referral.

# Differential Dx

## Endogenous

### Central
GnRH dependent

- Trauma
- CNS inection
- CNS tumour
- Radiotherapy
- Spina bifida
- Hydocephalus
- Hamartoma

### Peripheral
GnRH independent

- Ovarian
- Adrenal
- McCune Albright Syn.
- Hypothyroidism

## Exogenous

- O/C
- HRT
- E2 creams
- Soy?
- ‘Natural remedies’

# Case scenario 2

6 year old girl with 1 year hx of breast development. Otherwise well with no past hx of note

O/E she has

- Tanner 2-3 breast development
- Tanner 1 pubic hair
- Height on 90th%ile
- Mid parental height = 90$^{th}$%ile
- BA = 6 years

Summary – No evidence of sustained or progressive sex steroid excess.

# Differential Dx

## Premature Thelarche

### Endogenous (early)

**Central**
GnRH dependent

- Trauma
- CNS inection
- CNS tumour
- Radiotherapy
- Spina bifida
- Hydocephalus
- Hamartoma

**Peripheral**
GnRH independent

- Adrenal
- McCune Albright Syn.
- Hypothyroidism

### Exogenous

- O/C
- HRT
- E2 creams
- Soy?
- ‘Natural remedies’

# Premature Thelarche

- common
- variable breast development
- usually 1-4 years age
- no height velocity acceleration
- BA=CA
- No pubertal progression

# Diagnosis of isolated breast development

*When is referral required?*

If there is no evidence of sustained sex steroid exposure based on physical exam, growth data, or bone age close observation (initially 3 monthly) is appropriate.

If there are signs of progressive oestrogen exposure urgent referral to paediatric endocrinology is appropriate

# Boobs or Bust?
# What about breast development in boys?
# Case Scenario 3

- 14 year old boy presents with Tanner 3 breast development of ~12 months duration.
- Distressed by this – never goes swimming.
- In puberty: Tanner 3 genitalia and pubic hair and 10 ml testis.

# Differential Diagnosis

Non Pathological Gynaecomastia

- Neonatal
- Pubertal
  - 50-75% of pubertal boys (possibly more)
  - Often looks worse with obesity (as well as increased aromatisation).
  - Unless severe resolves in late puberty.
  - If structural breast changes have occurred the gynaecomastia may not resolve.

# Differential Diagnosis

Pathological

- Drugs
  - Marijuana
  - Antiandrogens
  - Oestrogens
  - Dopamine antagonists
  - H2 antagonists etc.
- Tumour associated
  - **hCG or LH secreting tumour**
  - Oestrogen secreting tumour
- Miscellaneous (Klinefelters, hypothyroidism, androgen insensitivity syndrome)
- Familial (X-linked recessive of sex limited dominant e.g. Tutankanum)

# What history is relevant?

- Are they in puberty?
- Are they fat?
- Medications/ drug abuse
- Evidence for elevated prolactin levels (nipple discharge)
- Is there any evidence/hx suggestive of hypogonadism
- Any evidence of an underlying endocrinopathy
- Family history of gynaecomastia.
- History of systemic illness ( eg renal, hepatic etc.)

# Relevant exam findings

- Breast(s) size and consistency(firm/soft)
- Nipple discharge
- Testis size/asymmetry
- Evidence of chronic illness
- Abdo - masses (adrenal/liver)
- Thyroid

# What investigations are appropriate?

- Investigations depend on the presentation. Minimal workup is needed for the obese adolescent male with gynaecomastia. It can often be difficult to tell whether there is real breast tissue there!
- But investigate more fully if the boy is
  - prepubertal
  - stuttering puberty
  - thin (at least not obese)
  - breast development is marked

# Investigations

- hCG *(tumour)*
- Karyotype *(Klinefelters)*
- Liver/renal *(evidence of chronic illness)*
- TFTs *(signs of hypo/hypethyroidism)*
- Basal Gonadotropins (LH and FSH) *(Klinefelters, primary hypogonadism)*
- *Prolactin*
- *Oestradiol*
- *Androgens*

# Treatment Options

- **Surgical -** if extreme or prolonged

- **Medical** (treat underlying condition/ remove offending medication or drugs)
  - **Decrease Oestrogen**
    - *Tamoxifen- selective estrogen receptor modulator (SERM)*

    *Dose 20mg daily – usually need for 1-2 years.*

# Case Scenario 4- Premature Pubarche

6 year old boy presents with 23 pubic hairs!

Hairs present for 2-3 months and slowly increasing in no.

Some body odor and a few comedomes.

# Pubic versus Vellous Hair

- Pubic hair is dark, thick and curly
- Vellous hair is fine and down like. It can be dark and quite long in certain ethnic groups (eg Mediterranean, Indian, Polynesian)

# Further work up

| | |
|---|---|
| Growth | height 75th %ile |
| | height velocity 95th%ile |
| Skin | Not pigmented, oily |
| Testis | 1ml bilaterally (pea sized) |
| Bone Age | 10 years |

# Early androgen signs

- pubic hair
- increasing genital size
- body odour
- acne and oily skin

# Early pubertal changes in boys

Gonadal examination makes the assessment of male puberty easier!

| | |
|---|---|
| Prepubertal | testis $\leq$ 3ml |
| Pubertal | testis $\geq$ 4 ml |

Increasing testicular size ***almost always*** indicates a central cause.

Prepubertal testis indicates a peripheral cause (almost always adrenal)

# Case Scenario - Summary

Evidence of sustained sex steroid with increased growth and advanced bone age.

Prepubertal testis size indicates a peripheral cause.

Warrants urgent referral to a paediatric endocrinologist

# Differential Dx

Endogenous

**Gonadal**

Androgen secreting tumour

**Adrenal**

Congenital adrenal hyperplasia

Androgen secreting tumour

hCG secreting tumour

Exogenous (rare)

Anabolic steroids

# Futher tests

Abdo (adrenal) and gonadal USS - may need CT

Androgen profile

- Androstenedione
- Testosterone/ free testosterone
- Dehydroepiandrosterone (DHEA)
- 17 OH progesterone *(for CAH)*
- Sex hormone binding globulin (SHBG)

# Case Scenario 5

6 year old  boy presents with 23 pubic hairs!

Hairs present for 2-3 months and slowly increasing in no.

Some body odour and a few comedomes.

Height velocity 50th%ile, Height 50th%ile

Bone Age = 7 years

testis < 1ml bilaterally

# Assessment and Differential Dx

No evidence of sustained sex steroid effect (normal height velocity and bone age)

PREMATURE ADRENARCHE most likely

- Commonest cause of premature pubarche
- occurs generally in mid childhood

# Adrenarche

- maturational increase in adrenal 17-ketosteroids
- results in increased DHEA (into pubertal range)
- no change in levels of other adrenal androgens
- none to small increase in growth velocity
- no advancement of bone age
- Usually the cause of early virilisation in boys and girls ie pubic hair development
- Biochemically present 1-2 years before pubarche

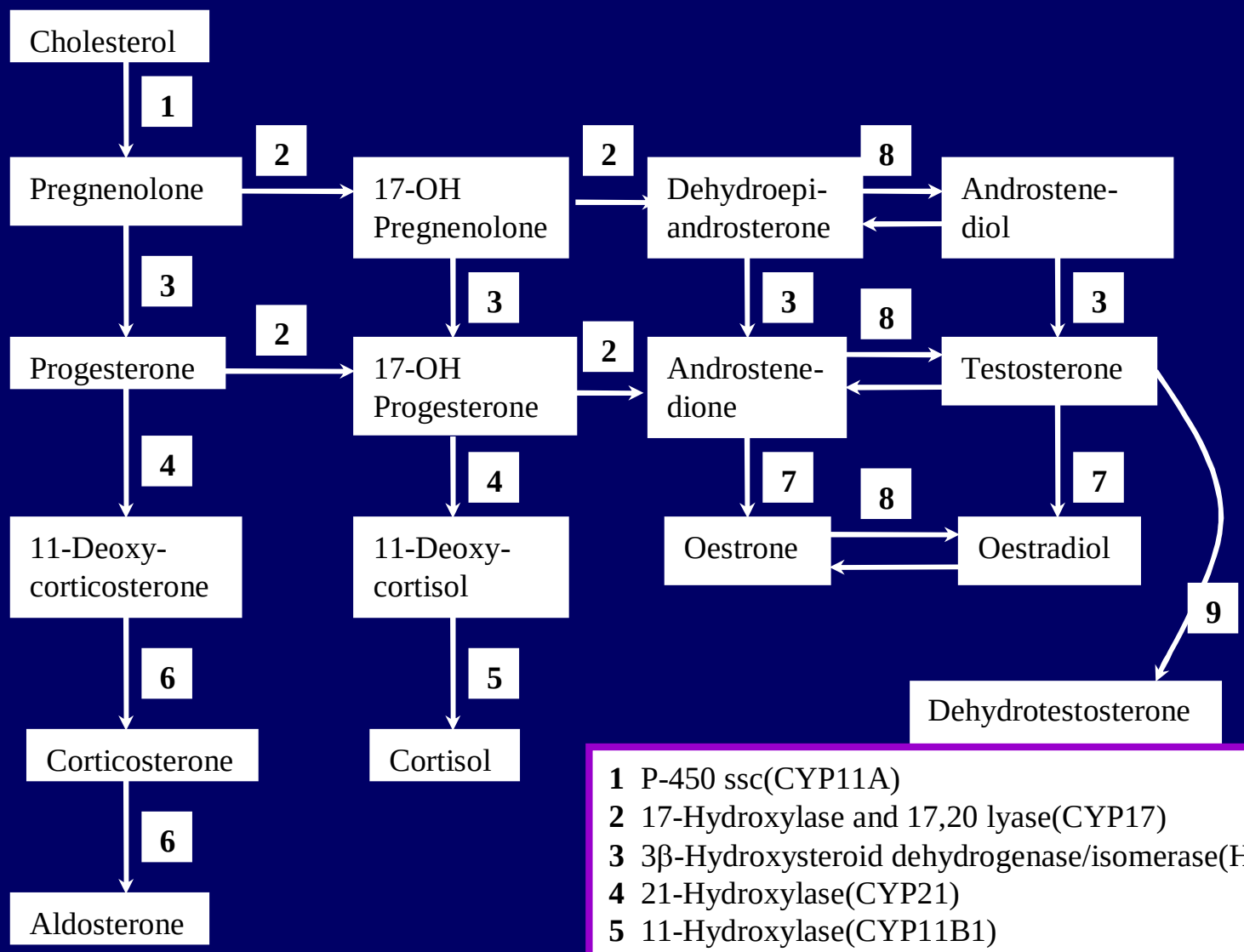


**1** P-450 ssc(CYP11A)
**2** 17-Hydroxylase and 17,20 lyase(CYP17)
**3** 3β-Hydroxysteroid dehydrogenase/isomerase(HSD3B2)
**4** 21-Hydroxylase(CYP21)
**5** 11-Hydroxylase(CYP11B1)
**6** Aldosterone synthetase(CYP11B2)
**7** Aromatase
**8** 17β-Hydroxysteroid dehydrogenase
**9** 5α reductase

# Management of premature pubarche

If there is no evidence for ongoing androgen exposure (ie growth acceleration, advanced bone age or ongoing virilisation) the diagnosis is likely premature adrenarche.

Observation for 1-2 years (4-6 monthly) to ensure no pubertal progression.

Underlying organic pathology (eg tumour or CAH) needs appropriate tx.

# Summary

- The assessment of early puberty is mainly clinical and auxological.
- A bone age is the only mandatory initial investigation.
- Sex steroids levels (with the exception of 17 hydroxy progesterone) are generally unhelpful and do not assist in the diagnosis.
- Precocious puberty is a symptom not a diagnosis.
- A GnRH stimulation test will reliably define those in true central precocious puberty.
- Treatment largely depends on the degree of final height compromise.